Congenital heart disease

Donna Page

Congenital heart diseases can range from small holes between heart chambers to severe abnormalities. Cardiovascular research scientist Donna Page discusses early heart development and the ongoing research that aims to identify the causes of CHD

AQA: 3.3.4 Mass transport in animals
Edexcel A: 1 Lifestyle, health and risk
Edexcel B: 4.4 Circulation
OCR A: 3.1.2 Transport in animals
OCR B: 2.2.1 The heart and monitoring heart function
WJEC Eduqas: 2.3.2 (b) and (c) The heart and the cardiac cycle

Key words

Heart
Development
Disease
Genetics
Human

This is a true story. It's April 1985, Los Angeles. Jeni is still 2 months away from being born — she will then most likely die. Jeni has been diagnosed with a heart defect called hypoplastic left heart syndrome. Her parents, Jill and Paul Sorenson, have been informed that Jeni's chances for survival are next to none and they need to choose between years of surgery, letting her die peacefully, or an unlikely heart transplant. Jill and Paul choose easily. Surgery.

Jeni was delivered by caesarean-section 2 weeks early and had her first open heart surgery almost immediately afterwards. Many more were to follow. Her diagnosis was fortunate, the action of a worried **gynaecologist** referring Jill to the Genetics Institute in Los Angeles. Jill's brother's baby had died of a heart defect. Jill's baby had a different syndrome, but this was enough to consider a possible genetic link, and it motivated Jill and Paul to try a different path.

Many **congenital** heart diseases (CHDs) are presumed to have a genetic origin, but some can be caused by environmental inputs including diabetes, long-term medicines taken by the mother, or even effects from maternal diet. Problems can be determined by listening to fetal heart sounds and by using **echocardiograms**. However, identification of the particular syndrome sometimes requires a DNA test. For many patients, the genetic defects are yet to be identified and the exact heart defects are often not known until after birth. With prior knowledge, surgical interventions can be planned following delivery and, with a greater understanding of the genetic problems, future treatments and interventions may be possible. To understand the origins of heart defects we must remind ourselves of the structure of the normal heart (see Box 1 and Figure 1) and appreciate the complexities of heart development.

Early heart development

Around 9 days after you became a zygote, you were implanted into the lining of your mother's uterus. In just over another week, your first blood vessels appeared and your heart started to form. For the vast majority of us, this resulted in a fully

Box 1 The mature heart

The mature heart has four distinct chambers, the left and right atria, and the left and right ventricles (see Figure 1). The right atrium receives deoxygenated venous blood from the body and this is directed to the right ventricle through the tricuspid valve. The right ventricle contracts to pump the blood to the lungs via the pulmonary artery, where the blood becomes re-oxygenated via gaseous exchange. Oxygenated blood is then directed to the left atrium of the heart through the pulmonary veins and is passed to the left ventricle via the mitral (bicuspid) valve. The left ventricle is responsible for pumping oxygenated blood to the rest of the body through the aorta and has a thicker muscular wall in comparison to the right ventricle.

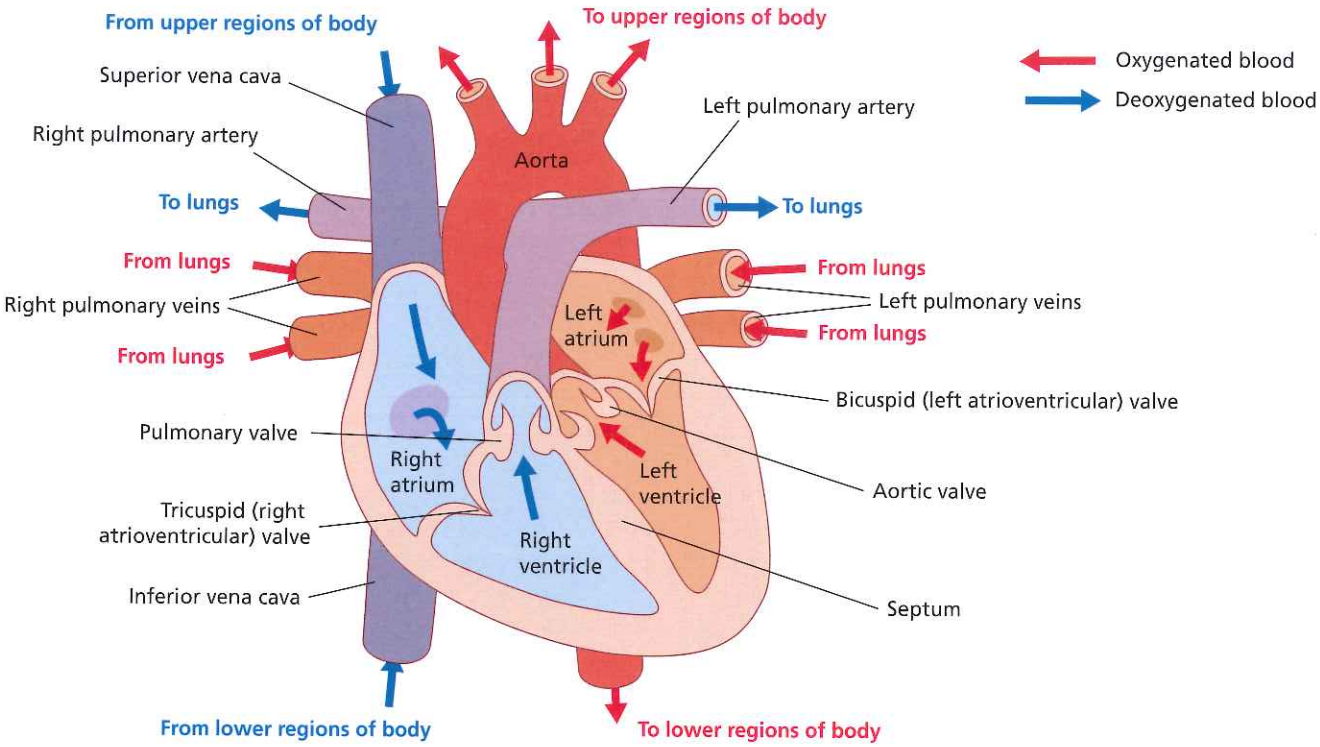

Figure 1 The mature heart structure showing blood flow

functioning organ. Sadly, for a few, defects result in fetal death or miscarriage and, for around 1% of newborns, some form of CHD due to developmental abnormalities.

The heart is the first organ to develop. The immature heart pumps nutrient-rich blood to developing tissues to support their growth. Malformation of the heart can have a major impact on embryonic development and is responsible for the highest fetal **mortality** rates. Such problems are the most common congenital defect and many children and adults affected by CHD also suffer from additional problems termed **co-morbidities**. These can include holes in the abdominal wall, which can mean that intestines or organs are found outside the body, or problems of the musculature and skeleton. 50% of cases with severe CHD suffer from neurodevelopmental disabilities. A detailed understanding of the developing heart is therefore crucial for our understanding of CHD and future treatments.

Terms explained

Amniotic cavity A closed sac containing amniotic fluid surrounding developing embryos.

Co-morbidities Diseases that frequently occur concurrently with another disease.

Congenital Having a trait from birth.

Echocardiogram The use of ultrasound to monitor heart function.

Germ layers Cell layers that form in the early embryo, in vertebrates: ectoderm, mesoderm and endoderm.

Gynaecologist A doctor specialising in female reproductive health.

Septum A wall dividing a structure into two.

A step-by-step process

Heart development is complex and happens in a series of well-defined steps that we know about from studies on the embryos of mice and chickens. An early key phase in animal development is the formation of three cell layers

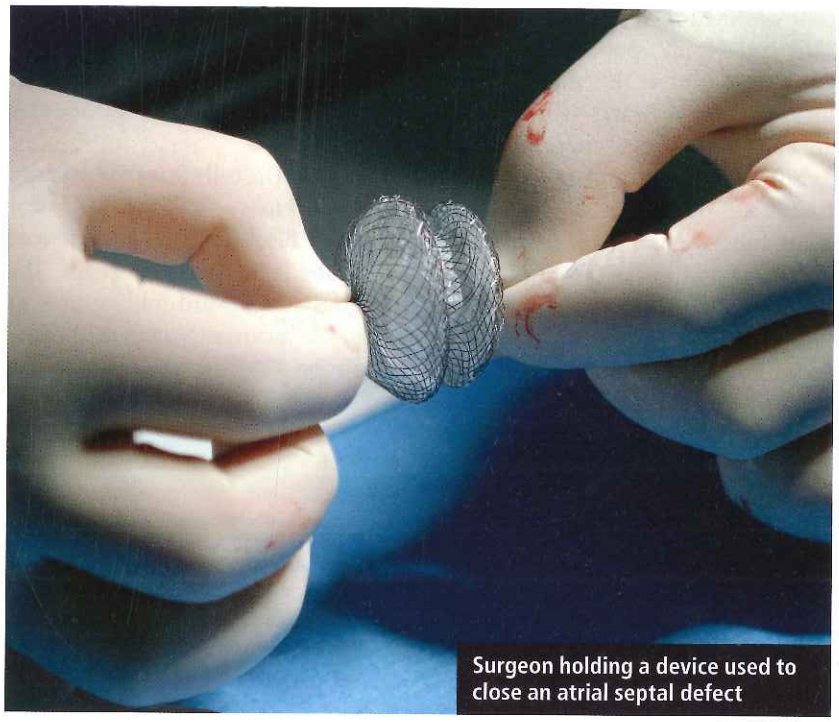

Surgeon holding a device used to close an atrial septal defect

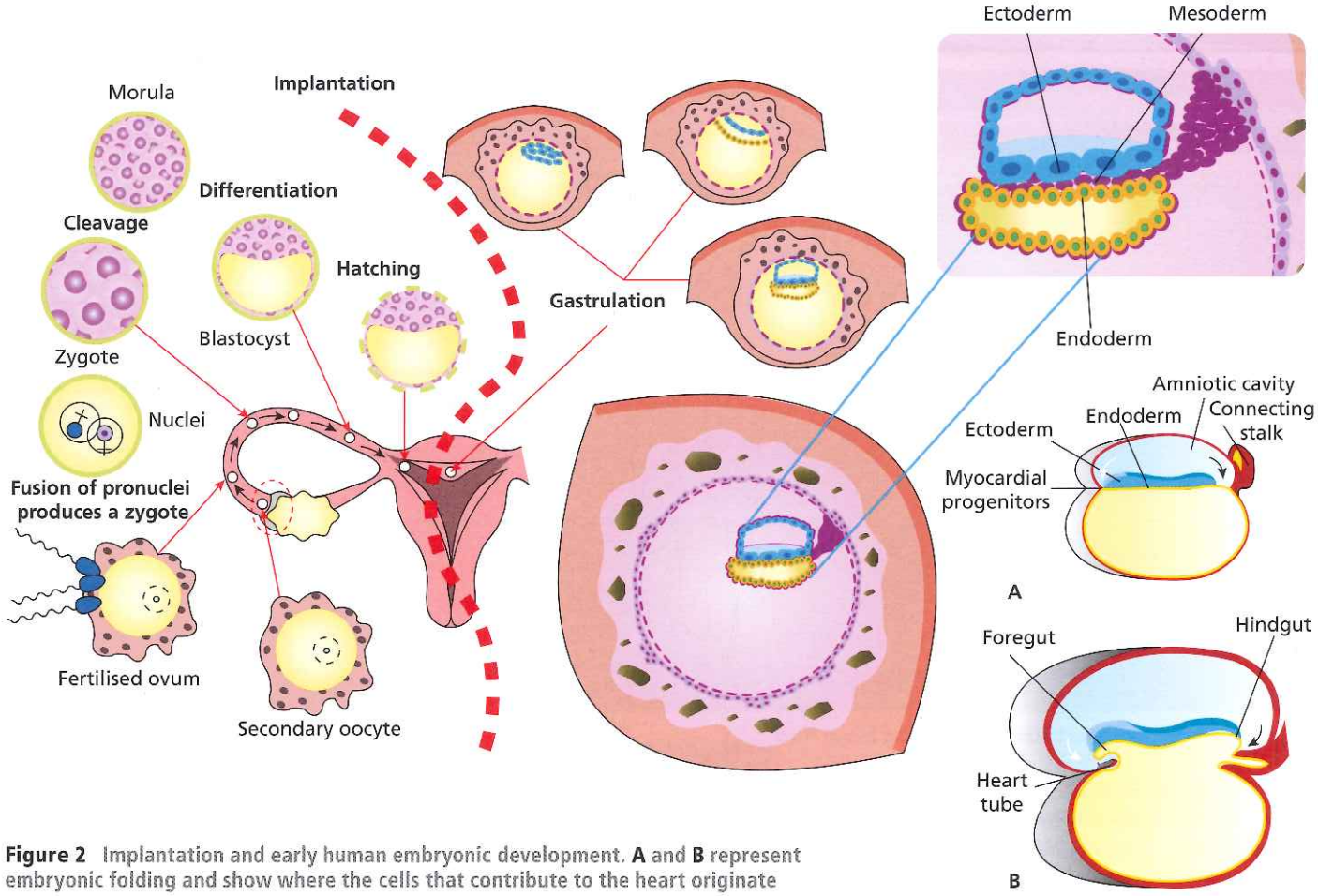

Figure 2 Implantation and early human embryonic development. **A** and **B** represent embryonic folding and show where the cells that contribute to the heart originate

during gastrulation, termed the ectoderm, mesoderm and endoderm (see Figure 2 and Box 2). Put simply, ectoderm will form your nervous system and skin, mesoderm your bones, muscles and heart, while the endoderm forms the lining of your gut and contributes to formation of other organs. The first cells destined to contribute to your heart are called myocardial progenitors. They come from a population of cells that emerges from the mesoderm during gastrulation. After this they form two cell populations that contribute to the formation of the heart — the primary and secondary heart fields. Together they are called the cardiac crescent (see Figure 3).

Successful development requires cells to migrate. The cells from the primary heart field move together into the middle of the embryo to form the linear heart tube. Cells migrating from the secondary heart field make the front (anterior) and back (posterior) of the heart tube, generating the poles. The linear heart tube then elongates and undergoes a rightward folding process known as heart looping. During this process, the atrioventricular (AV) canal forms and separates the regions of the heart tube that will contribute to the future atria and ventricles. The heart continues to loop to the right to begin to form the four heart chambers and the outflow tract. Additionally, the precursors of the tricuspid and mitral (bicuspid) valves form in the AV canal. In the outflow tract, a **septum** will form, separating the outflow tract into the aorta and pulmonary artery. Division of the heart into chambers then arises by a process known as septation, resulting in two distinct atria

Box 2 Early human embryonic development

Human oocytes are fertilised in the fallopian tubes. The subsequent zygote divides by mitosis to form a ball of 32 cells (a morula) before forming a blastocyst, with a cavity. This then implants into the uterus. At this stage an inner cell mass undergoes the processes of differentiation and gastrulation forming the three **germ layers** and the **amniotic cavity**. The position of the myocardial progenitors in the mesoderm is now apparent (see Figure 2).

Box 3 Researching CHD

CHDs cover a wide spectrum of structural malformations and arise from many causes that range from genomic variation to environmental exposure. These conditions are further complicated by a high degree of phenotypic variability and no single gene can be held accountable for every case within a disease subset. For these reasons, genome-wide approaches studying large cohorts of patients with a similar CHD phenotype have been adopted to try to identify new CHD candidate genes. These techniques include genome-wide association studies, copy number variant analysis and next generation sequencing technologies such as whole exome sequencing and whole genome sequencing.

Corrective heart surgery is sometimes necessary at a very young age

and ventricles. The outflow tract then remodels, forming the aorta and pulmonary artery and the chambers and vessels become fully integrated, giving the heart its basic structure (see Figure 3).

Congenital heart disease

Development is an amazing process and it is perhaps surprising that for most of us nothing goes wrong. For those for whom it is not a perfect process, CHD is the most common type of birth defect, accounting for one-third of all major anomalies present at birth. Until corrective heart surgery was introduced in the 1950s, less than 15% of babies born with CHD reached adulthood. The success of heart surgery now means that survival to adulthood has risen to 90%. However, many CHD sufferers will experience further complications later in life, such as problems with heart valves, heart rhythm, heart failure and sudden death in a small number of cases. This is because heart surgery only corrects the structural abnormalities. The underlying cause of the CHD still remains and can have consequences later in life. Additionally, scar tissue on the heart may develop after the corrective surgery and this can also interfere with the normal functioning of

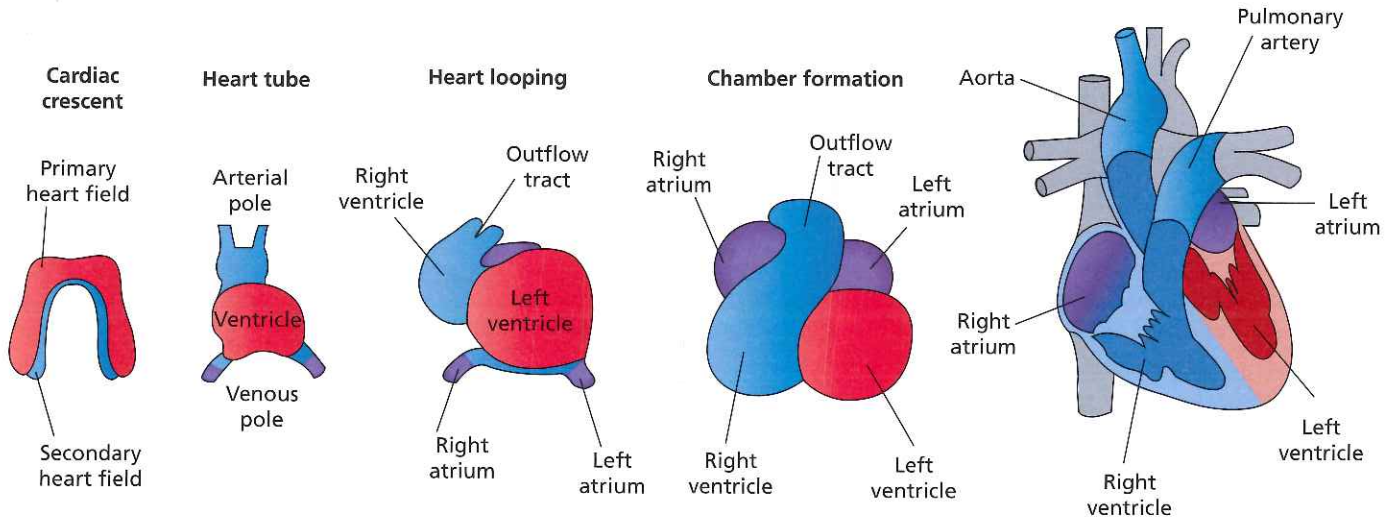

Figure 3 The stages of heart development

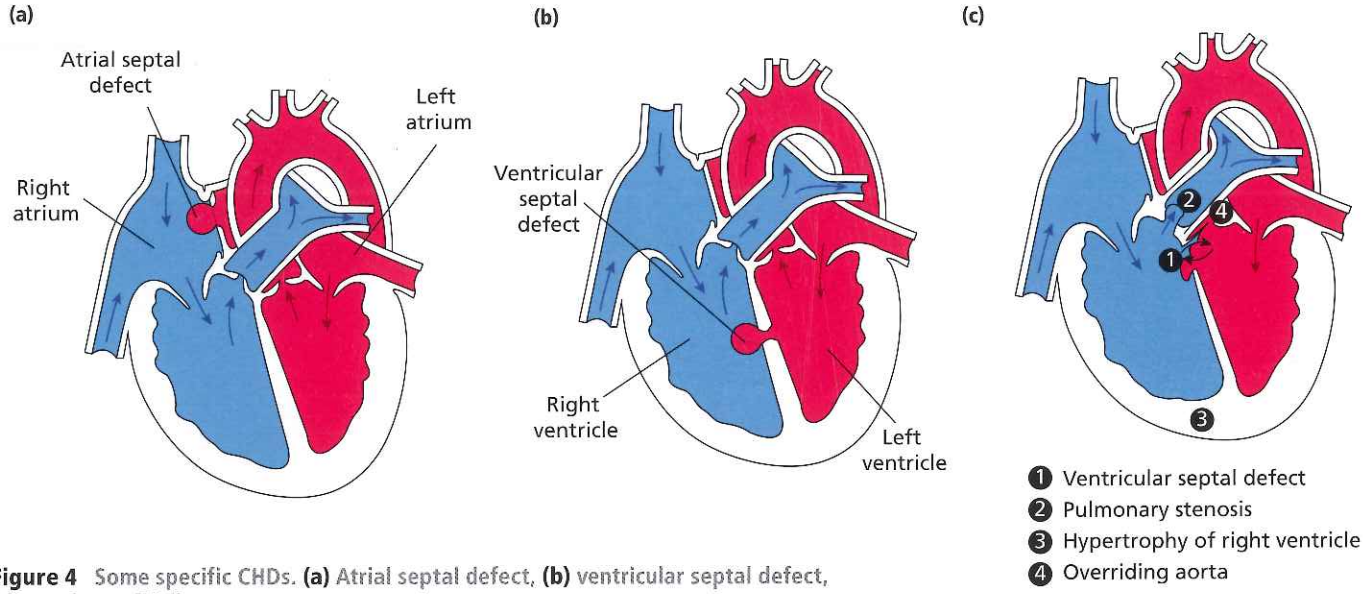

Figure 4 Some specific CHDs. **(a)** Atrial septal defect, **(b)** ventricular septal defect, **(c)** tetralogy of Fallot

the heart. Unfortunately, who will go on to suffer severe complications cannot be predicted, since, for the majority of patients, the cause of the CHD is not identified. Only 10–20% of cases of CHD have an identifiable cause, whether it is a known chromosomal abnormality, such as chromosome 22q11 deletion or trisomy 21 (Down syndrome), or an associated environmental factor, such as maternal diabetes. The remaining 80% of patients with CHD are managed based on the presentation of their disease. Establishing new treatments for CHD is therefore a significant challenge.

Types of CHD

There are many different types of CHD which are categorised by the presence or absence of specific structural features (see Figure 4). The most common CHDs are septal defects, which are sometimes referred to as 'a hole in the heart'. Septal defects occur due to incomplete partitioning between the two atria (atrial septal defect, ASD) or two ventricles (ventricular septal defect, VSD) during septation. Many small septal defects close up on their own, whereas larger septal defects require corrective surgery.

Another common type of CHD, which is more severe, is tetralogy of Fallot (TOF). TOF is a combination of four specific heart defects that occur due to malformation of the outflow tract. They include a VSD, a narrow pulmonary valve, thickening of the right ventricular wall and a displaced aorta (see Figure 4c). This combination of heart defects causes 'cyanosis', which means the oxygen content of the blood is lower than normal and the affected individual may appear blue. This is because oxygenated blood and deoxygenated blood become mixed together as a result of the abnormal heart structure.

Other CHDs can also cause cyanosis, such as transposition of the great arteries, which happens when the pulmonary artery and aorta switch positions when the outflow tract is remodelled. As a result, the aorta is supplied by the right ventricle and the pulmonary artery protrudes from the left ventricle.

Remember Jeni? She had hypoplastic left heart syndrome. The left side of her heart had not developed properly, almost as though she was left with half a heart. The left ventricle was not efficient and the bicuspid valve and aorta were smaller than they should be. But with surgery, she graduated from school, got married and is still living in California. You can read her story, and the stories of others, in the 'Further reading' links.

Further reading

Watch a short YouTube movie that summarises CHD, its causes and current research: **www.youtube.com/watch?v=669a2Qd17I8**

The different types of congenital heart defects with Illustrations can be found here: **www.heartpoint.com/congheartdx.html**

Read Jeni's story: **https://tinyurl.com/yb32q7cm**

How does it feel to have a CHD? Children and young people were asked to write, in their own words, about the challenges of living with CHD: **https://tinyurl.com/y8jqfyqk**

American television host Jimmy Kimmel discusses his son's CHD: **www.youtube.com/watch?v=MmWWoMcGmo0**

Donna Page is a lecturer at Manchester Metropolitan University. Donna models human cardiovascular and developmental diseases in zebrafish, which enable live imaging of cardiovascular development and function.

Key points

- Heart defects are the most common congenital disease.
- Congenital heart diseases can have genetic and environmental causes.
- Surgery has had major successes for CHD patients.
- New genetic research will provide new treatment options.